

Shurygina I.A.¹, Shurygin M.G.^{1,3}, Rodionova L.V.¹, Chepurnykh E.E.^{1,2}, Ayushinova N.I.¹

EXPRESSION OF COLLAGENS IN THE DAMAGE AREA AT ABDOMINAL ADHESIONS

¹ Irkutsk Scientific Centre of Surgery and Traumatology
(ul. Bortsov Revolyutsii 1, Irkutsk 664003, Russian Federation)² Irkutsk State Medical University
(ul. Krasnogo Vosstaniya 1, Irkutsk 664003, Russian Federation)³ Pharmasynitez, J.S.C.
(ul. Krasnogvardeyskaya 23, Irkutsk 664007, Russian Federation)

Background. Postoperative adhesions are a serious problem in surgery. However, at the present time molecular mechanisms of the adhesion process are insufficiently studied.

Aim. To study the dynamics of expression of genes encoding the synthesis of collagen in case of damage to the serosa on the example of the peritoneum in conditions of aseptic inflammation.

Materials and methods. Aseptic inflammatory process in the abdominal cavity was modeled (Wistar rats, n = 40). A micro- and macroscopic picture of the damage area was studied. Immunofluorescent staining for Type I collagen (Col 1A1) was performed. The expression of genes encoding collagen of different types was evaluated using the RT²-Profiler PCR kit Array Rat Wound Healing.

Results. It has been established that the adhesion process with peritoneal damage in aseptic conditions reaches its maximum by the 30th day of observation. The same period coincides with the maximum of collagen synthesis in fibroblasts in the repair area, revealed by immunofluorescence study. The interrelation of synthesis of type I and III collagens went as expected – the onset of expression of type III collagen (from day 3) is ahead of the expression of collagen type I (from day 7). Peak gene expression of collagens type I, Alpha-1 and -2; type III Alpha-1, type IV Alpha-1 and -3, type V Alpha-1, -2 and -3; type XIV Alpha-1 (Col14a1) falls on the 14th day. For the first time, active involvement of type V alpha-3 collagen in the adhesion process was noted - we detected both early (from day 1) and maximum intensive (up to 166.96 times increase in comparison with intact animals).

Conclusion. Perhaps, the hyperexpression of collagen V alpha-3 that we revealed is an important link in the pathogenesis of adhesion in the abdominal cavity.

Key words: peritoneal adhesions, collagen, collagen Va3, modelling

ЭКСПРЕССИЯ КОЛЛАГЕНОВ В ЗОНЕ ПОВРЕЖДЕНИЯ ПРИ РАЗВИТИИ СПАЕЧНОГО ПРОЦЕССА В БРЮШНОЙ ПОЛОСТИ

Шурыгина И.А.¹, Шурыгин М.Г.^{1,3}, Родионова Л.В.¹, Чепурных Е.Е.^{1,2}, Аюшинова Н.И.¹¹ ФГБНУ «Иркутский научный центр хирургии и травматологии»
(664003, г. Иркутск, ул. Борцов Революции, 1, Россия)² ФГБОУ ВО «Иркутский государственный медицинский университет» Минздрава России
(664003, г. Иркутск, ул. Красного Восстания, 1, Россия)³ АО «Фармасинтез»
(664007, г. Иркутск, ул. Красногвардейская, 23, Россия)

Послеоперационная спаечная болезнь является серьезной проблемой в хирургии, однако на настоящий момент молекулярные механизмы развития спаечного процесса остаются недостаточно изученными. Цель исследования: изучить динамику экспрессии генов, кодирующих синтез коллагена, при повреждении серозной оболочки на примере брюшины в условиях асептического воспаления.

В эксперименте моделировали асептический воспалительный процесс в брюшной полости, изучали микро- и макроскопическую картину зоны повреждения, осуществляли иммунофлюоресцентное окрашивание на коллаген I типа. Установлено, что процесс спайкообразования при повреждении брюшины в асептических условиях достигает максимума к 30-м суткам наблюдения. В этот же срок отмечается и максимум синтеза коллагена в фибробластах в зоне репарации, что отмечено при иммунофлюоресцентном исследовании. Впервые выявлено активное вовлечение коллагена типа V альфа-3 в процесс спайкообразования: отмечено как раннее (с 1-х суток), так и максимально интенсивное (кратность повышения до 166,96 раза по сравнению с интактными животными) его повышение. Возможно, выявленная нами гиперэкспрессия коллагена V альфа-3 является важным звеном в патогенезе спайкообразования в брюшной полости.

Ключевые слова: спаечная болезнь, коллаген, коллаген Va3, моделирование

INTRODUCTION

Postoperative adhesions are a serious problem in surgery. The causes of adhesive process could be trauma, bacterial infection, bleeding, and foreign bodies in the abdominal cavity. However, at the present time the molecular mechanisms of the adhesion process are insufficiently studied [1, 8].

It is well known that collagen fibers form the basis of connective tissue [6]. At present, 28 types of collagen

are distinguished, which are encoded by more than 40 genes. They differ in molecular organization, organ and tissue affiliation. More than 90 % of all collagen of higher organisms is in collagen types I, II, III and IV [5].

The basis of connective tissue is collagen of type I and III. According to immunomorphological analysis, type III collagen forms the basis of collagen fibers of connective tissue and immature fibers of granulation tissue, while coarse and mature fibers consist mainly of type I col-

lagen. In the process of collagen biosynthesis during the formation of the scar, the type I collagen predominates. It is assumed that this collagen is synthesized by fully differentiated fibroblasts, and that, due to its structural stability, it provides more favorable biomechanical parameters of the forming scar in the period of insufficient maturity of the type I collagen fibers. The total accumulation of collagen in the scar tissue is the main factor determining the mechanical properties of the scar. Types I, III, IV and VIII are secreted by myofibroblasts [9]. The remaining types of collagen are less well known.

Acquiring new knowledge on the regulation of collagen formation will allow us to search for mechanisms of the pathogenesis of the adhesion process and methods for targeted correction of disorders.

AIM

To study the dynamics of expression of genes encoding the synthesis of collagen in case of damage to the serosa on the example of the peritoneum in conditions of aseptic inflammation.

MATERIALS AND METHODS

Aseptic inflammatory process in the abdominal cavity was modeled by opening a serous-muscular layer of the cecum 1 cm long, followed by suturing the wound with a Schmiden-type suture and scarifying the parietal peritoneum of the right lateral canal 1.5 × 1.5 cm in size [2, 3]. 40 male Wistar rats weighing 220–250 g at the age of 9 months were used to model the process. Simulation was performed using ketamine anesthesia (ketamine 50 mg/kg, droperidol 2.5 mg/kg and atropine 0.4 mg/kg). The experiments were carried out in accordance with the norms of humane treatment of animals, which are regulated by the Guidelines of the Association for Assessment and Accreditation of Laboratory Animal Care, international according to a protocol approved by the ethical committee of the Irkutsk Scientific Centre of Surgery and Traumatology.

Sacrificing was carried out under ketamine anesthesia at 8 time points within a period from 2 hours to 30 days. Visual assessment of the severity of adhesive process was carried out in accordance with the developed protocol (Table 1) [2, 4].

Fixation of the material was carried out in a FineFix solution (Milestone, Italy). After fixing, wiring and paraffin processing was performed; serial sections were made

with a thickness of 3 μm; hematoxylin-eosin stains were used and by Van Gieson method for detection of collagen fibers. Immunofluorescent staining of the preparations was carried out. Antibodies to collagen type I Col 1A1 (D-13) goat polyclonal IgG (Santa Cruz, Cat. N Sc-25974, Lot # B0310), working dilution 1:300, were used as primary antibodies. As a secondary antibody, antibodies Alexa fluor 488 donkey anti-goat IgG (H + L) (Invitrogen, Cat. N A-1105 Lot 870969), working dilution 1:300. The cores were stained with DAPI (Biotium, Cat. N 40011, Lot 8D 0605), a working dilution of 1:50.

To study the collagen expression, the material was taken from the area of damage in the region of the cecum, was placed in a solution of RNAlater (Ambion, Canada, Cat # 7020). After 12 hours exposure at +4 °C, the material was stored in a freezer at -20 °C. As a control we used serum-muscle cecal layer of intact animals (n = 5).

To isolate the total RNA, the RNeasy Mini Kit was used (Qiagen GmbH, Germany, Cat No.74104). For DNase purification of RNA we used Rnase-Free DNase Set, (Qiagen GmbH, Germany, Cat. No. 79254, Lot No. 139294845). At the end of the incubation, the samples were purified with the RNeasy Mini Kit (Qiagen GmbH, Germany, Cat No. 74104). The cDNA-RT2 First Strand Kit (Qiagen GmbH, Germany, Cat No. 330401, Lot No. DC08-8) was used to prepare the cDNA. To evaluation expression of genes encoding collagens we used the RT²-Profiler PCR kit Array Rat Wound Healing (Qiagen GmbH, Germany, Cat No. 330503).

Statistical processing of the obtained results was carried out with the use of the original on-line program for analyzing data sets obtained on the arrays RT²-Profiler PCR ARRAY from SA Bioscience (<http://www.qiagen.com>).

RESULTS

In simulating peritoneal injury in aseptic conditions, after 6 hours, we noted hyperemia of the peritoneum and fibrin deposits. Microscopic examination observed swelling of the submucosal layer; hemorrhage, moderate neutrophil infiltration of the submucosal layer; areas not covered by mesothelium, thickening and neutrophil infiltration of the peritoneum in places adjacent to the lesion zone, expressed neutrophil infiltration in the intestinal suture zone.

24 hours after the injury, the animals retained a mild hyperemia of the peritoneum, fibrin deposits on the peritoneum. In 80 % of cases, the formation of adhesions “gut

Macroscopic scale of severity of adhesive process in the abdominal wall

Table 1

Points	Number of adhesions	Morphology	Extension of adhesions	Intestinal deformation
0	Absent	NA	NA	NA
1	Solitary adhesion (intervisceral or viscera-parietal)	Membranous	1 anatomical region (coecum)	Light, w/o luminal narrowing
2	2 adhesions (intervisceral or viscera-parietal)	Loose, non-vascularized	1 abdomen level (coecum + other organs)	Medium deformation w/o luminal narrowing
3	>2 adhesions (intervisceral or viscera-parietal)	Dense, non-vascularized	2 abdomen levels	Deformations and luminal narrowing up to 1/2
4	Adhesions mass	Dense, vascularized	>2 abdomen levels	Severe deformations and luminal narrowing >1/2

- omentum", "gut - abdominal wall", "gut - gut" was noted. In the area of adhesions and in the area of the intestinal suture, severe neutrophil infiltration of the peritoneum was observed. Three days after injury, slight hyperemia of the peritoneum and fibrin deposits preserved. In 80 % of cases we observed adhesions, microscopic examination at the area of adhesions marked the growth of young granulation tissue, characterized by a large area of commissures, tight connective tissue, expressed inflammation around the suture.

On day 7, all animals showed adhesions, and in 80 % adhesions masses and coarse adhesions of the "gut - gut" type were formed. In 100 % of observations, adhesions were multiple - 3-4 adhesions were recorded in one animal. In 40 % of cases, adhesions resulted in severe deformation and narrowing of the intestine, as well as swelling of the superjacent parts, which is regarded as a prerequisite for the development of acute intestinal obstruction. Microscopic examination showed tight adhesions of large length without expressed vascularization, and revealed the formation of a capsule around the suture.

On the 14th day the adhesion process was registered in all animals, multiple adhesions of the type "gut - gut", "gut - omentum", "gut - abdominal wall" were revealed. In 60 % of cases, adhesions resulted in severe deformation and narrowing of the intestine, as well as swelling of the superjacent parts. Microscopic examination revealed tight vascularized adhesions, proliferation of connective tissue around the suture.

By day 30, the degree of adhesion in the abdominal cavity reached its maximum. In all cases, multiple adhesions were formed, including the most prognostically unfavorable ones, such as "gut - gut" type. In 60 % of cases, adhesions resulted in severe deformation and narrowing of the intestine, swelling of the superjacent parts. Microscopic examination revealed wide adhesions with well vascularized collagen fibers of high density.

With the use of a scoring evaluation of the adhesion process, it was found that in the period from 2 hours to day 1 the degree of adhesion process was moderate, with further observation the intensity of the adhesion process increased, reaching its maximum by day 30 (Fig. 1).

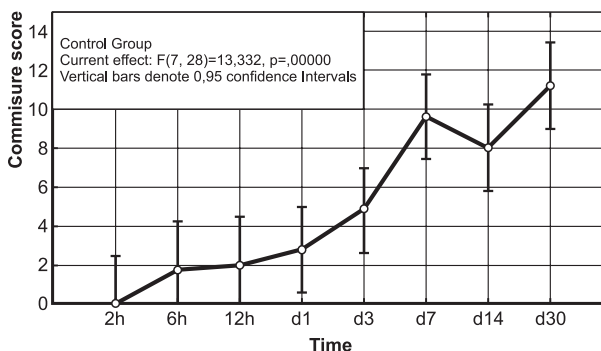


Fig. 1. Intensity of adhesions in abdominal cavity.

We studied the expression of procollagen type I Col1A1 in fibroblasts in the lesion area during reparative process after peritoneal injury. As is known, Col1A1 encodes the main component of type 1 collagen - the pro-alpha1 (I) chain, from which extracellularly type 1 collagen is formed, the main component of connective tissue. Therefore, the level of Col1A1 allows to dynamically evaluate the synthetic activity of fibroblasts at the studied moment.

Immunofluorescence study showed that in animals the positive Col1A1 staining was first registered on day 14 - single cells were brightly colored in the area of adhesions. By day 30 the number of such cells in the area of adhesion increased, and a huge number of these cells were found with a bright specific color.

The expression of genes encoding collagens was evaluated in the area of injury of the cecal serous-muscular

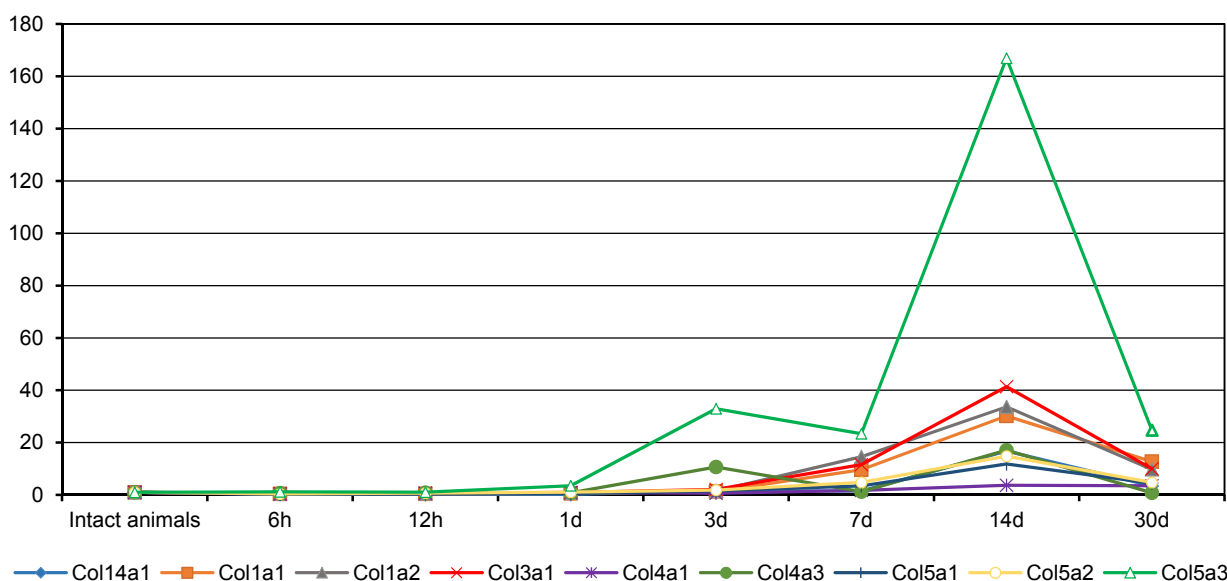


Fig. 2. Expression of genes encoding the synthesis of collagen, in the area of injury. Note: Col1a1 - Collagen, type I, Alfa-1; Col1a2 - Collagen, type I, Alfa-2; Col3a1 - Collagen, type III, Alpha-1; Col4a1 - Collagen, type IV, Alpha-1; Col4a3 - Collagen, type IV, Alpha-3; Col5a1 - Collagen, type V, Alpha-1; Col5a2 - Collagen, type V, Alpha-2; Col5a3 - Collagen, type V, Alpha-3; Col14a1 - Collagen, type XIV, Alpha-1.

layer. The results are presented with accordance to gene expression in intact animals.

We studied the expression of collagen genes of type I, Alfa-1 (Col1a1), type I, Alfa-2 (Col1a2); type III, Alfa-1 (Col3a1), type IV, Alpha-1 (Col4a1); type IV, Alpha-3 (Col4a3); type V, Alpha-1 (Col5a1); type V, Alpha-2 (Col5a2); type V, Alfa-3 (Col5a3); type XIV, Alpha-1 (Col14a1).

It was found that in the area of adhesions, expression of type V Alfa-3 collagen was earlier than others, it was 3.51 times higher than the level of intact animals within 24 hours after peritoneal injury. Expression of the genes of type III collagen, known as "early" collagen of the wound process, was noted only on day 3 (2.06 times increase compared to the control). By the day 7, we marked activation of the expression of all the collagen types studied, except for type XIV.

Hyperexpression of all the studied genes responsible for the synthesis of collagen accounted for 14 days. The maximal activation in comparison with intact animals was recorded for type V collagen Alpha-3 (166.96 times), type III, Alfa-1 (41.36 times), type I, Alfa-1 and Alfa-2 subtypes (30.30 and 33.67 times, respectively). By the day 30, the activity of expression of all types of collagens decreased.

CONCLUSION

Thus, we found that the process of adhesion with peritoneal injury in aseptic conditions reaches its maximum by the 30th day of observation. The same period coincides with the maximum of collagen synthesis in fibroblasts in the repair area, as revealed by immunofluorescence study. At the same time, a decrease in the expression of collagen genes practically to "background" values in the injury area indicates the lack of potential for further growth of collagen synthesis and the completion of the adhesion process in the abdominal cavity. The interrelation of the synthesis of well-studied collagen types I and III coincided with the expected - the onset of expression of type III collagen was ahead of the expression of type I collagen.

What stands out is the active involvement of type V alpha-3 collagen in the adhesion process revealed for the first time - we noted its both early (from day 1), and highest possible increase (up to 166.96 times in comparison with intact animals). Until now, this type of collagen has been poorly studied. During reparation of the musculocutaneous wound, only a short-term expression of pro- α 3 (V) collagen was detected, and its level was much lower than for other collagen genes in the area of trauma [10]. It is known that other collagen V subtypes (alpha-1 and alpha-2) are included in type I collagen fibers and can regulate the diameter of collagen type I fibrils [7]. Perhaps, the hyperexpression of collagen V alpha-3 that we revealed is an important link in the pathogenesis of adhesion in the abdominal cavity.

REFERENCES

1. Аюшинова Н., Шурыгина И., Чепурных Е., Шурыгин М., Григорьев Е. Спаечная болезнь брюшной полости – междисциплинарная проблема // Врач. – 2017. – № 5. – С. 8–10.
- Ayushinova N, Shurygina I, Chepurnykh E, Shurygin M, Grigoriev E. (2017). Adhesive disease of abdominal

cavity – interdisciplinary problem [Spaechnaya bolezny' bryushnoy polosti – mezhdistsiplinarnaya problema]. *Vrach*, (5), 8-10.

2. Аюшинова Н.И., Шурыгина И.А., Шурыгин М.Г., Лепехова С.А., Балыкина А.В., Малгатаева Е.Р., Попова А.Д., Янкевич С.А. Экспериментальная модель для разработки способов профилактики спаечного процесса в брюшной полости // Сибирский медицинский журнал (Иркутск). – 2012. – Т. 109, № 2. – С. 51–53.

Ayushinova NI, Shurygina IA, Shurygin MG, Lepekhova SA, Balykina AV, Malgatayeva ER, Popova AD, Yankelevich SA. (2012). Experimental model for the development of prevention of adhesions in the abdominal cavity [Eksperimental'naya model' dlya razrabotki sposobov profilaktiki spaechnogo protsesssa v bryushnoy polosti]. *Sibirskiy meditsinskiy zhurnal (Irkutsk)*, 109 (2), 51-53.

3. Способ моделирования спаечного процесса в брюшной полости: Патент № 2467401 Рос. Федерация; МПК G09B 23/28 (2006.01) / Аюшинова Н.И., Лепехова С.А., Шурыгина И.А., Рой Т.А., Шурыгин М.Г., Зарицкая Л.В., Гольдберг О.А.; заявитель и патентообладатель Учреждение Российской академии медицинских наук Научный центр реконструктивной и восстановительной хирургии Сибирского отделения РАМН (НЦРВХ СО РАМН). – № 2011131678/14; заявл. 27.07.2011; опубл. 20.11.2012. – Бюл. № 32.

Ayushinova NI, Lepekhova SA, Shurygina IA, Roy TA, Shurygin MG, Zaritskaya LV, Goldberg OA. (2012). Method for modeling the adhesion process in the abdominal cavity: Patent N 2467401 of the Russian Federation [Sposob modelirovaniya spaechnogo protsesssa v bryushnoy polosti: Patent № 2467401 Ros. Federatsiya].

4. Шурыгина И.А., Аюшинова Н.И., Шурыгин М.Г. Оценка эффективности и безопасности применения Адепт для профилактики спайкообразования в брюшной полости в эксперименте // Новости хирургии. – 2017. – Т. 25, № 1. – С. 14–19.

Shurygina IA, Ayushinova NI, Shurygin MG. (2017). Evaluation of the effectiveness and safety of Adept application for the prevention of adhesion in the abdominal cavity in the experiment [Otsenka effektivnosti i bezopasnosti primeneniya Adept dlya profilaktiki spaykoobrazovaniya v bryushnoy polosti v eksperimente]. *Novosti khirurgii*, 25 (1), 14-19.

5. Шурыгина И.А., Шурыгин М.Г., Аюшинова Н.И., Каня О.В. Фибробласты и их роль в развитии соединительной ткани // Сибирский медицинский журнал (Иркутск). – 2012. – Т. 110, № 3. – С. 8–12.

Shurygina IA, Shurygin MG, Ayushinova NI, Kanya OV. (2012). Fibroblasts and their role in the development of connective tissue [Fibroblasty i ikh rol' v razvitii soedinitel'noy tkani]. *Sibirskiy meditsinskiy zhurnal (Irkutsk)*, 110 (3), 8-12.

6. Flavell SJ, Hou TZ, Lax S, Filer AD, Salmon M, Buckley CD. (2008). Fibroblasts as novel therapeutic targets in chronic inflammation *Br J Pharmacol*, 153, 241-246.

7. Imamura Y, Scott IC, Greenspan DS. (2000). The pro-alpha3(V) collagen chain. Complete primary structure, expression domains in adult and developing tissues, and comparison to the structures and expression domains of the other types V and XI procollagen chains. *J Biol Chem*, 275 (12), 8749-8759.

8. Katada J, Saito H, Ohashi A. (2005). Significance of cyclooxygenase-2 induced via p38 mitogen-activated protein kinase in mechanical stimulus-induced peritoneal adhesion in mice. *J Pharmacol Exp Ther*, 313 (1), 286-292.

9. Musso O, Rehn M, Saarela J, Théret N, Liétard J, Hintikka, Lotrian D, Campion JP, Pihlajaniemi T, Clément B. (1998). Collagen XVIII is localized in sinusoids and base-

ment membrane zones and expressed by hepatocytes and activated stellate cells in fibrotic human liver. *Hepatology*, 28, 98-107.

10. Sumiyoshi H, Kitamura H, Matsuo N, Tatsukawa S, Ishikawa K, Okamoto O, Fujikura Y, Fujiwara S, Yoshioka H. (2012). Transient expression of mouse pro- α 3(V) collagen gene (Col5a3) in wound healing. *Connect Tissue Res*, 53 (4), 313-317. doi: 10.3109/03008207.2011.653061.

Information about the authors

Shurygina Irina Aleksandrovna – Doctor of Medical Sciences, Professor of RAS, Deputy Director for Science of Irkutsk Scientific Centre of Surgery and Traumatology (664003, Irkutsk, ul. Bortsov Revolyutsii, 1; tel. (3952) 29-03-69; e-mail: irinashurygina@gmail.com)

Shurygin Mikhail Gennadyevich – Doctor of Medical Sciences, Head of the Scientific Laboratory Department of Irkutsk Scientific Centre of Surgery and Traumatology; Director for Science and Innovations, Pharmasyntez, J.S.C. (664007, Irkutsk, ul. Krasnogvardeyskaya, 3, office 3; e-mail: shurygin@rambler.ru)

Rodionova Lyubov Viktorovna – Candidate of Biological Sciences, Head of the Laboratory of Cell Pathophysiology and Biochemistry, Irkutsk Scientific Center of Surgery and Traumatology (tel. (3952) 29-03-50; e-mail: greidmacho@yandex.ru)

Chepurnykh Elena Evgenyevna – Candidate of Medical Sciences, Academic Secretary, Irkutsk Scientific Centre of Surgery and Traumatology; Associate Professor at the Department of Advanced Level Surgery, Irkutsk State Medical University (e-mail: chepurnykh.ee@yandex.ru)

Ayushinova Natalia Ilyinichna – Candidate of Medical Sciences, Surgeon at the Unit of Purulent Surgery N 1, Irkutsk Scientific Centre of Surgery and Traumatology (664049, Irkutsk, Yubileyniy, 100; e-mail: katnatlove@mail.ru)